

Bio-Magnetic Resonance, Inc.
30781 Stephenson Highway
MADISON HEIGHTS, MI 48071
(248) 585-5115
FAX (248) 585-0234

The Imaging Center
15670 Southfield Road
ALLEN PARK, MI 48101
(313) 294-2897
FAX (313) 294-2915

Bio-Magnetic Resonance, Inc.
25100 Kelly Road
ROSEVILLE, MI 48066
(586) 445-4900
FAX (586) 445-4902

Biomagnetic Imaging Center
960 River Centre Drive
PORT HURON, MI 48060
(810) 966-8523
FAX (810) 966-5056

The Imaging Center
4447 Talmadge, Suite H
TOLEDO, OH 43623
(888) 674-8653
FAX (888) 674-8650

(888) MRI-TODAY
(674-8632)
www.biomagmri.com

EXAM DATE: 11/29/2008

PATIENT NAME: [REDACTED]

PATIENT ID: [REDACTED]

LOCATION: BIO MAGNETIC RESONANCE INC.

SEX: F
DOB: 11/21/1961

REFERRING PHYSICIAN: [REDACTED]

EXAMINATION: BRAIN MRI WITH AND WITHOUT MAGNEVIST

FINAL REPORT

CLINICAL HISTORY:

47-year-old female with vertigo. We are asked to rule out a neoplasm of the inner ear.

MR IMAGING PROTOCOL:

Multi-planar multi-sequences MR images of the brain pre and post infusion. Internal auditory canal protocol was used.

MR FINDINGS:

Diffusion weighted images show no evidence of restrictive diffusion abnormality to suggest an acute stroke or bleed. The cortical volume is normal. The grey-white matter differentiation is normal.

No significant white matter abnormalities are seen.

The lateral ventricles are normal in size and symmetric bilaterally. The 3rd and 4th ventricles are midline. The rest of the subarachnoid system is within normal limits. Normal vascular flow voids are seen. The sella and parasellar regions are normal. The craniocervical junction is normal. The calvarium, skull base and soft tissues of the scalp are normal.

No pathologic enhancement is seen.

Internal auditory canals and 7th and 8th nerve complexes are normal bilaterally.

Dictated: Sehgal, Vivek MD 11/30/2008 10:13 AM
Transcribed: Corcoran, Patricia 12/01/2008 12:33 PM
Electronically signed: Sehgal, Vivek MD 12/01/2008 02:25 PM

EXAM DATE: 11/29/2008

PATIENT NAME: [REDACTED]

PATIENT ID: [REDACTED]

LOCATION: BIO MAGNETIC RESONANCE INC.

SEX: F
DOB: 11/21/1961

Bio-Magnetic Resonance, Inc.
30781 Stephenson Highway
MADISON HEIGHTS, MI 48071
(248) 585-5115
FAX (248) 585-0234

The Imaging Center
15670 Southfield Road
ALLEN PARK, MI 48101
(313) 294-2897
FAX (313) 294-2915

Bio-Magnetic Resonance, Inc.
25100 Kelly Road
ROSEVILLE, MI 48066
(586) 445-4900
FAX (586) 445-4902

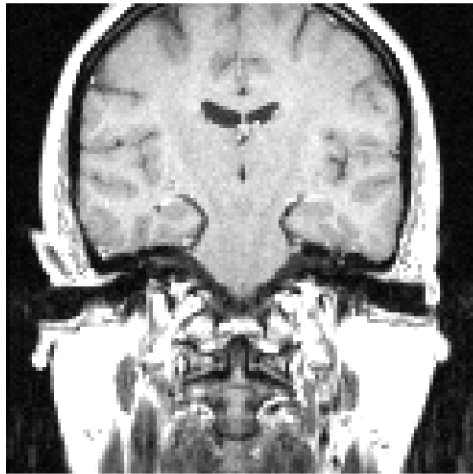Biomagnetic Imaging Center
960 River Centre Drive
PORT HURON, MI 48060
(810) 966-8523
FAX (810) 966-5056

The Imaging Center
4447 Talmadge, Suite H
TOLEDO, OH 43623
(888) 674-8653
FAX (888) 674-8650

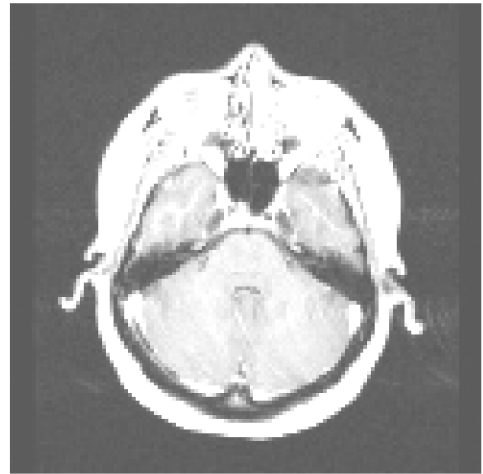
(888) MRI-TODAY
(674-8632)
www.biomagmri.com

IMPRESSION:

Normal study.



Series 16, Image 8



Series 15, Image 6

Thank you for your referral.

Dictated: Sehgal, Vivek MD 11/30/2008 10:13 AM
Transcribed: Corcoran, Patricia 12/01/2008 12:33 PM
Electronically signed: Sehgal, Vivek MD 12/01/2008 02:25 PM